

# We are IntechOpen, the world's leading publisher of Open Access books Built by scientists, for scientists

7,100

Open access books available

189,000

International authors and editors

205M

Downloads

Our authors are among the

154

Countries delivered to

TOP 1%

most cited scientists

12.2%

Contributors from top 500 universities



WEB OF SCIENCE™

Selection of our books indexed in the Book Citation Index  
in Web of Science™ Core Collection (BKCI)

Interested in publishing with us?  
Contact [book.department@intechopen.com](mailto:book.department@intechopen.com)

Numbers displayed above are based on latest data collected.  
For more information visit [www.intechopen.com](http://www.intechopen.com)



# Neuroregenerative-Rehabilitative Therapy for Spinal Cord Injury

*Alok Sharma, Hemangi Sane, Nandini Gokulchandran, Prerna Badhe, Amruta Paranjape, Pooja Kulkarni and Vivek Nair*

## Abstract

Spinal cord injury is one of the leading causes of disability worldwide. Current mainstay treatment strategies consist of surgical and medical management in acute and subacute stage. Rehabilitative management in the chronic stage. None of the existing strategies can repair the damage to the spinal cord and recover neurological functioning. Stem cells have promising results in pre-clinical and clinical studies. Various pre-clinical studies have evidenced neuro-regenerative capabilities of stem cells and shown neural recovery. Clinical studies have also shown improvements in neurological functions and quality of life. This chapter discusses about different types of cells available, routes of administration available to transplant these cells, dosages of cell and optimum time after injury at which cells should be transplanted based on world-wide literature. We have also discussed results following our protocol of intrathecal transplantation of autologous bone marrow mononuclear cells. Although, not a cure, stem cell therapy further improves quality of life, functional independence and reduces secondary complications when combined with existing treatment strategies; neuroregenerative rehabilitative therapy.

**Keywords:** stem cell therapy, autologous, bone marrow mononuclear cells, spinal cord injury, paracrine effect, neurorestoration

## 1. Introduction

Spinal cord injury (SCI) is a disabling neurologic disorder that can lead to motor and sensory impairment causing, paraplegia or tetraplegia. It can also exhibit bladder and bowel impairment, respiratory impairment and autonomic dysfunction [1].

The incidence of the disease is estimated to be 223–755 per million worldwide [2, 3]. The healing and recovery process during different phases since the time of injury differ significantly [4].

Current treatment options consist of surgical management complimented by administration of methylprednisolone in the acute stage; prevention of secondary injury in the sub-acute stage and multidisciplinary rehabilitation management in the chronic stage. Due to insufficient neuroregenerative capabilities of these treatments, they fail to reverse the damage to neurons and symptoms of neurological deficit [5–8]. Therefore, there is an unmet medical need which warrants exploring novel neurorestorative strategies.

Stem cell therapy has emerged as a promising regimen to bring about neuro-regeneration and neural functional benefits, hence can be termed as neuroregenerative therapy. Various cell types being explored for their effectiveness are bone mesenchymal stem cells (BMSCs), bone marrow mononuclear cells (BMMNCs), umbilical cord-derived mesenchymal stem cells (UCMSCs), adipose-derived stem cells (ADSCs), olfactory ensheathing cells (OECs), and fetal brain-derived neural stem/progenitor cell (FB-DNS/PCs), induced pluripotent stem cells (iPSCs) and others [9–12].

The earliest attempt in translational research were by Geron Corporation who had announced a clinical trial using human embryonic stem cell (ESC)-derived oligodendrocyte progenitor cells (OPCs) in patients with spinal cord injury at the site of the lesion [13]. Due to ethical and safety risks involved in ESC they were not widely accepted for clinical use. Advent of knowledge of the role of adult stem cells in natural repair processes of the body lead to clinical exploration of these cells. Some of the earliest published work was by Geffner et al. in 2008, by transplantation of adult bone marrow stem cells through multiple routes, that is, intraspinal, intrathecal and intravenous in patients with SCI [14]. The study demonstrated that these cells and routes were safe and feasible. Many adult stem cell types, routes and clinical protocols have since been tested clinically [14–33].

Clinical outcome and effectiveness of cell transplantation remains variable due to the heterogeneity of cell types, dosages, route of transplantation, level of manipulation and treatment regimens followed thereafter. This chapter provides a detail review about different stem cell therapies available for the management of spinal cord injury and their clinical outcomes as seen in published literature.

## **2. What are stem cells?**

Stem cell is an undifferentiated cell, which can self-renew to replicate itself as well as give rise to the specialized cells under appropriate conditions [34].

Stem cells are the undifferentiated cells that can give rise to progeny identical to themselves (de-differentiation) or specialized cells different from them (trans-differentiation). All regenerative processes in the human body during developmental pre-natal stages as well as post-natal and adult stages follow these two routes. Recently, the technological advances have given rise to another route, reprogramming cells to acquire properties of trans-differentiation [35].

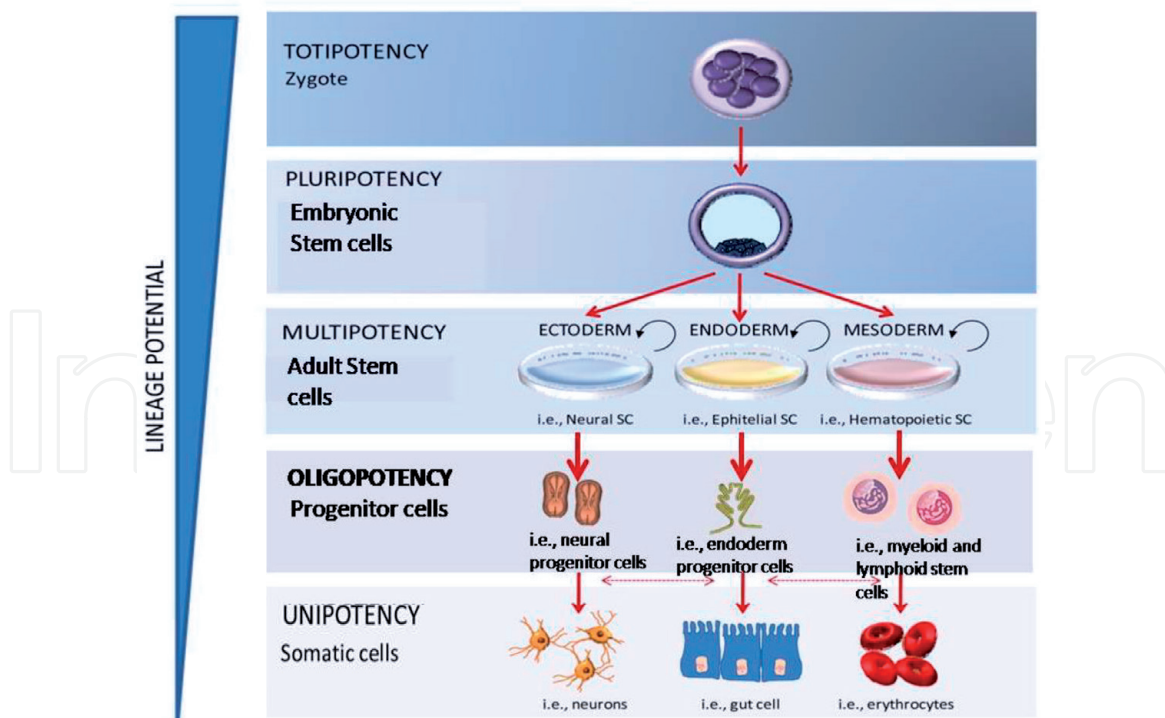
Depending upon their ability to de-differentiate or transdifferentiate, the source of cells, processing required to harvest the cells and host in which cells are transplanted; the cells can be categorized into various types which are described in detail in the next section.

## **3. Types of stem cells**

### **3.1 Based on the potency of cells**

Depending upon their differentiation potential, cells are classified as unipotent, multipotent, pluripotent and totipotent (**Figure 1**).

Totipotent cells can differentiate into embryonic as well as extraembryonic and placental cells [36]. Pluripotent cells can differentiate into embryonic cells only.



**Figure 1.**  
 Different types of cells based on their potency.

These possess the property of de-differentiation as well as trans-differentiation into cell types of all three germ layers [36]. Cells that can be harvested after birth are called ‘adult stem cells’. Most of the adult stem cells are multipotent or unipotent. Multipotent cells possess the property of trans-differentiation into cells of different tissues whereas unipotent cells can only de-differentiate to create progeny identical to themselves or a differentiated cell type of only one specific tissue [37].

### 3.2 Based on the host in whom cells are transplanted

If the cells are harvested from and transplanted to the same person, these are called autologous cells; but if the cells are harvested from a host different from that of the recipient these are called allogenic cells.

## 4. Mechanism of action of stem cells in spinal cord injury

### 4.1 Remyelination

The immediate impact of injury to spinal cord is on the ascending and descending pathways and blood vessels in the spinal cord. Disrupted circulation leads to infarction of the local tissue due to hypoxia and ischemia causing neuronal loss and demyelination. This is clinically presented as spinal shock, systemic hypotension, vasospasm, ischemia, ionic imbalance and neurotransmitter accumulation [38]. Transplantation of cells can remyelinate damaged tissue and aid in symptom recovery. Human ESC-derived OPCs transplanted into the rats with spinal cord injury showed enhanced remyelination and locomotor ability when transplanted in the sub-acute phase as opposed to chronic phase after spinal cord injury [39]. Neural precursor cells also showed differentiation into oligodendrocytes ensheathing the

axons, these cells expressed myelin suggesting the remyelination potential of these cells. Rat models, both in sub-acute and chronic phase of spinal cord injury showed improved functional outcome. Remyelination was better in sub-acute as compared with chronic phase [40]. Human UCB cells transplanted 7 days after spinal cord injury in the rats also showed remyelination of axons improving functional outcome [41]. Similar results were observed using adult bone marrow mononuclear cells [42].

#### 4.2 Anti-inflammatory effect

Inflammation in response to the injury is both protective and damaging to the tissue. Secondary injury is perpetrated by uncontrolled inflammatory response pro-inflammatory cytokine release [43–46]. Various studies have explored anti-inflammatory effect of MSCs, NPCs, BMMNCs, ESCs and UCB cells. Cell transplantation reduces the expression of pro-inflammatory cytokines TNF $\alpha$ , IL-4, IL-1 $\beta$ , IL-2, IL-6, IL-7, IL-12 and interferon gamma [47–50].

#### 4.3 Neoangiogenesis

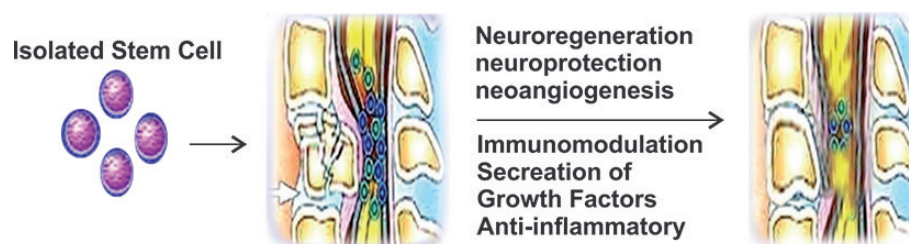Transplanted cells have been shown to secrete various growth factors and stimulate the resident cells to secrete these factors through their paracrine effect. One of the growth factors secreted is vascular endothelial growth factor (VEGF) which stimulates neoangiogenesis. This proangiogenic effect has been evidenced by increased vascularization of the lesion area in various preclinical studies [51–54].

#### 4.4 Neuro-regeneration

Transplanted cells of various cells possess neurogenic potential. Cells have been shown to differentiate into neuronal as well as non-neuronal tissues. Axon sprouting is noticed in the transplanted regions. Endogenous neurogenetic processes are also catalyzed by the growth factors like brain-derived neurotrophic factor (BDNF) secreted by these cells. Synaptic pruning is also observed. These changes are further reinforced by the functional locomotor recovery seen post transplantation [55, 56].

#### 4.5 Neurotrophic and antiapoptotic effect

Cells secrete and facilitate endogenous secretion of various growth factors like fibroblast growth factor (FGF), vascular endothelial growth factor (VEGF), neural growth factor (NGF), glial cell line-derived neurotrophic factor and brain-derived neurotrophic factor (BDNF). These yield neurotrophic effect protecting the neurons from secondary injury and apoptosis (**Figure 2**) [54, 57].



**Figure 2.**  
*Bone marrow aspiration.*



## 5. Literature review of published evidence for efficacy of stem cells

### 5.1 Pre-clinical

#### 5.1.1 Human embryonic stem cells (hESCs)

These cells can be harvested from preimplantation blastocyst after immunosurgical removal of trophectoderm to access the inner cells mass [58]. hESCs are pluripotent and can differentiate into cells of ectodermal origin, that is, neuronal and glial cells. hESCs derived oligodendrocyte progenitor cells (OPCs) have shown neuronal recovery more effectively in the acute phase as compared to chronic phase of spinal cord injury [39, 59, 60]. Neural stem cells (NSCs) have the potential to differentiate into neural and non-neural tissue. Neuroregenerative potential of these exhibited as remyelination of damaged axons and secretion of neurotrophic factors enhancing neuronal survival post SCI in mice [61–63].

Despite promising results in pre-clinical studies, clinical translation of these is limited due to ethical concerns, risk of immune rejection and tumorigenicity [64].

#### 5.1.2 Multipotent stem cells

Adult stem cells like bone marrow stromal cells (BMSCs), mesenchymal stem cells (MSCs), umbilical cord stromal cells (UCSCs), umbilical cord mesenchymal cells (UC-MSCs), adipose-derived stem cells and dental pulp-derived stem cells are examples of multipotent stem cells [51]. MSCs and BMSCs are easy to harvest as they are available in the bone marrow. However, MSCs are available in a small number and therefore need to be expanded in-vitro before transplantation. These cells can migrate and home onto the site of injury therefore can be administered through a less invasive route distant from the site of injury. Unlike pluripotent cells, these cells show better functional recovery in chronic SCI [41, 42, 65]. Transplantation of these cells has shown functional and motor recovery in rats after SCI in several studies. These benefits are postulated to be due to neurotrophic, immunomodulatory and neoangiogenic effect of these cells in addition to their ability to differentiate neural cells [66].

#### 5.1.3 Induced pluripotent stem cells (iPSCs)

Last decade has seen rise in efforts to develop technologies to improve quality and efficiency of reprogramming of cells to induce pluripotency. iPSCs are also pluripotent and give rise to neuronal as well as non-neuronal tissue. Transplantation of progenitors derived from iPSCs have shown ability for remyelination of damaged neurons and improved nerve conduction. These cells can migrate long distances and therefore can be administered at a remote site which is less invasive. Apart from neuroregeneration, the cells are also capable of immunomodulation and synaptic reconstruction [67–72].

The technology is still in its nascent stage, although promising, successful clinical translation has barriers.

### 5.2 Clinical

#### 5.2.1 Embryonic stem cells (ESCs)

One of the earliest studies used cells from the fetal nervous and hemopoietic tissues in 15 SCI patients with no side effects [73]. However, due to various ethical

and medical concerns the use of these cells in clinical trials and application is restricted worldwide.

### *5.2.2 Multipotent stem cells*

Various studies have explored and demonstrated safety and feasibility of multipotent stem cells [15, 17, 74–83].

#### *5.2.2.1 Bone marrow mononuclear cells*

In a comparison between transplantation of autologous bone marrow cells directly into the SCI sites administered with subcutaneous injections of granulocyte macrophage colony stimulating factor (GM-CSF) {n = 5} and only administration of GM-CSF {n = 1}, combination group showed better improvements. Improvements were noted during 3–7 months post procedure, 1 patient from the combination group showed change in the AIS grade as well. There were mild side effects associated with GM-CSF administration like Fever, myalgia and leukocytosis; however, there were no irreversible adverse events noted, neither was there any neurological deterioration [16]. Kumar et al. studied the effect of bone marrow mononuclear cells and noted that there was perceptible improvement in 32.6% of the patients with no major irreversible adverse effects. Outcome did not vary with the time taken from the injury till intervention [35]. Al-Zoubi et al. demonstrated the positive effect of purified autologous leukapheresis-derived CD34+ and CD133+ stem cells in 19 cases of chronic SCI [29]. Our published results with mononuclear cells are discussed in detail in the later part of the chapter [84, 85].

#### *5.2.2.2 Mesenchymal cells*

In a novel method, using combination of bone marrow mesenchymal stem cells (BM-MSK) and patient's autoimmune T cells, Moviglia et al. demonstrated the neuro-regeneration phenomenon-based changes in the inflammatory processes at the site of injury. Both the patients showed motor and sensory recovery with no adverse effects [17]. Peripheral stem cells and macrophages have also been reported to show improvements of motor and sensory functions without any adverse effects [18, 19]. Cheng et al. in a controlled study including 34 cases of thoracolumbar spinal cord injury, stated that umbilical cord mesenchymal stem cells effectively improve neurological functional recovery after spinal cord injury, and its efficacy is superior to that of rehabilitation therapy and self-healing [30].

#### *5.2.2.3 Others*

Other sources such as cord blood, olfactory ensheathing cells and adipose tissue derived stem cells also showed improvement in sensory-motor functional improvements [20–24]. Saberi et al. studied the safety of intramedullary Schwann cell transplantation in 33 patients over the period of 2 years, there were no tumor formation or other adverse events recorded [25].

#### *5.2.2.4 Co-transplantation of multiple cell types*

Co-transplantation of cells has also been explored. Combined use of olfactory ensheathing cells and Schwann cells enhanced functional recovery [27]. Similarly,

Chen et al. in their study of 28 cases showed beneficial effects of OECs, SCs, or a combination of them in SCI [28].

Multipotent adult stem cells are safe to use clinically and have demonstrated improved neurological outcome.

### *5.2.3 Routes of transplantation*

Several comparative studies have been carried out to determine the optimum route of administration. Geffner et al. reported administration of BMSCs intravenous, into the spinal canal and into the spinal cord to be safe and feasible. They also demonstrated improved ASIA, Barthel Index, Ashworth and Frenkel scores suggesting improved quality of life in most patients [14]. While intra-arterial transplantation of autologous bone marrow stem cells showed more improvements as compared with that of intravenous route, intravenous transplantation showed better neurological outcome as compared to the site of injury [31–33]. Systemic routes show considerable dilution of cells at various cells like kidneys, liver, spleen and lungs. Several intraspinal approaches like intraparenchymal, intralesional and intramedullary approaches have been explored. Although no serious adverse events were noted; some patients complained of transient increase in paresthesia and muscle cramps. Intraspinal approaches are associated with increased risk of procedure related adverse effect due to invasive nature of the procedure [86–88]. Saito et al. [89], Pal et al. [90] and Kumar et al. [91] reported intrathecal administration to be the optimum route of administration. Although in this approach cells are transplanted away from the lesion area, MRI studies of radiolabeled cells have shown successful homing of cells at the site of injury [92].

## **6. Published clinical results of NeuroGen Brain and Spine Institute**

### **6.1 Our protocol**

#### *6.1.1 Pre-intervention protocol*

All the patients are thoroughly assessed clinically to rule out presence of active infections, HIV or HBsAg positive status and malignancies. Routine serological tests and chest X-ray are performed to ensure medical fitness. Neuroimaging using functional MRI brain and MRI of spine is performed. Various clinical outcome measures are marked before procedure assessing muscle tone, strength, ambulation and sensations. Granulocyte colony stimulating factor injections are given 48 and 24 h prior to the transplantation to enhance proliferation of cells in the bone marrow.

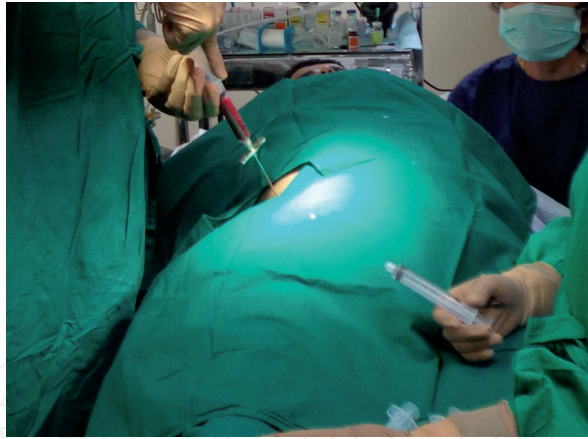
#### *6.1.2 Intervention protocol*

Our protocol has been designed after careful review of available literature. The protocol for harvesting and transplanting the cells is minimally invasive with no major adverse effects. It consists of three steps.

##### *6.1.2.1 Aspiration of bone marrow*

80–120 ml of bone marrow is aspirated from anterior superior iliac spine (**Figure 3**).





**Figure 3.**  
*Separation of BMMNCs.*

#### 6.1.2.2 Separation of BMMNCs

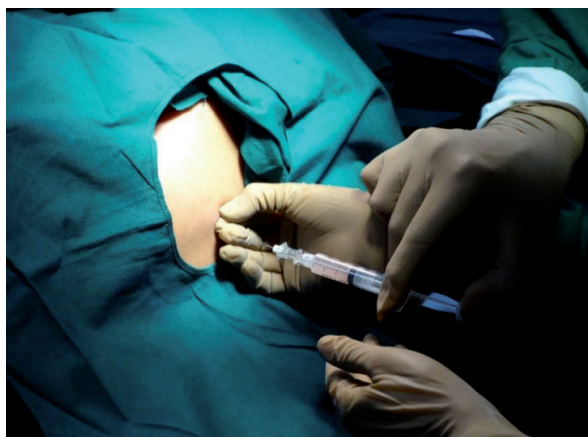Density gradient method is used to separate the bone marrow mononuclear cell fraction which is then analyzed under microscope using Trypan blue to check for viability of the mononuclear cells. FACS analysis is used to identify CD34+ cells and viability, cell count and percentage of CD34+ cells are calculated (**Figure 4**).



**Figure 4.**  
*Injection of BMMNCs.*

#### 6.1.2.3 Injection

Separated cell fraction is transplanted intrathecally in the space between L4 and L5 lumbar vertebrae by lumbar puncture. This is performed under local anesthesia and sterile conditions in the operation theatre (**Figure 5**).



**Figure 5.**  
*Mechanism of action of stem cells for the treatment of spinal cord injury.*

### *6.1.3 Post intervention protocol*

After the cell transplantation a home program of rigorous rehabilitation is prescribed. Many of the patients show deficiencies due to prolonged immobility and poor nutrition, therefore nutritional supplements are prescribed as and when required. Patients are regularly followed up every 3 months.

### *6.1.4 Rationale for the protocol*

Autologous cells are used to reduce the risk of immune rejection. Bone marrow mononuclear cells (BMMNCs) fraction consists of various cell types including mesenchymal cells, hematopoietic progenitor cells, side population cells, stromal cells and very small embryonic like cells. BMMNCs have demonstrated neurogenic potential and exhibit various paracrine effects like angiogenesis, upregulation of anti-inflammatory cytokines, secreting neurotrophic factors and growth factors, bring about immune modulation and stimulate resident stem cells. While the less invasive systemic routes, lead to dilution of the cells reaching the target organ, due to filtration of cells in various organs like liver, spleen, kidneys and lungs; more invasive routes like intra-spinal routes pose risk of procedure related adverse effect. Intra-thecal delivery therefore ensures delivery of maximum cells at the site of the injury with relatively reduced risk of procedure related adverse effects.

#### *6.1.4.1 Role of rehabilitation*

It is important that regenerative therapies are complimented with rehabilitative therapies like physiotherapy, occupational therapy, aquatic therapy, speech therapy, psychological intervention and nutritional advice. Regular goal-oriented rehabilitation provides neuroprotective, myoprotective, anti-inflammatory, antioxidant and neoangiogenic effects on a systemic level which resonate with the paracrine effects of cell therapy and compliment the effect of cell therapy. It is also believed that exercise can contribute to sub-granular and sub-ventricular neurogenesis. Neurogenesis consists of various processes. While differentiation, migration and axonal guidance are independent of physical activity synaptic pruning and plasticity is dependent of physical activity and therefore rehabilitation plays a pivotal role in enhancing this. Therefore, we prescribe a regime of multidisciplinary rehabilitation to be followed at home after the cell transplantation (**Figure 2**).

#### *6.1.5 Adverse effects*

This protocol is safe without any major adverse effects. We have so far treated more than 800 patients with spinal cord injury and none of the patients have exhibited any major irreversible adverse effects. A small percentage of patients have shown some minor procedure related adverse effects in SCI which are headache, pain at the site of injection, nausea and vomiting. These are usually self-limiting or can be completely relieved with minor medical intervention.

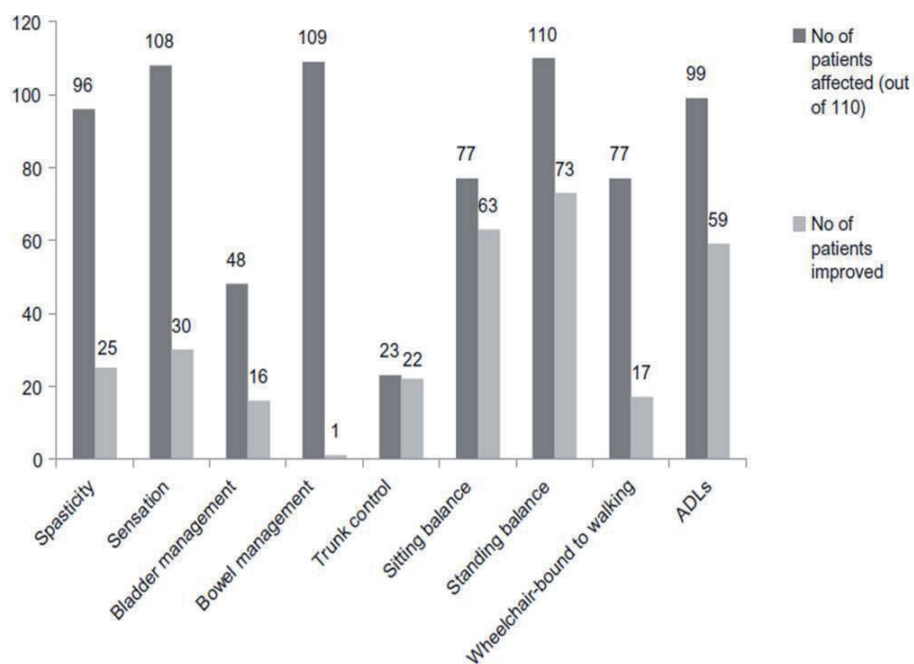
## **6.2 Published results**

### *6.2.1 Thoracolumbar spinal cord injury*

A detailed analysis of chronic thoracolumbar SCI patients who underwent intrathecal administration of autologous bone marrow mononuclear cells followed by neurorehabilitation was conducted [84]. The study sample included 110 thoracolumbar SCI patients. The outcome was recorded at a mean follow up of

2 years ± 1 month. The outcome measures were functional independence measure (FIM) score, American Spinal Injury Association scale (ASIA) and detailed neurological assessment. Data were statistically analyzed using McNemar’s Test to establish significance between the change in symptoms and the intervention.

A total of 100 out of 110 (91%) patients showed improvements. Improvement in trunk control was observed in 95.6% cases, bladder management in 33% with respect to shift from indwelling and condom catheter to self-intermittent catheterization, partial sensory recovery in 27% and reduction of spasticity in 26%. All the patients showed improvement in postural hypotension. 38% wheelchair bound patients started walking with assistance. Functionally, 27% showed improved activities of daily living (ADLs) and 53.6% showed a positive change in FIM score. About 10% cases showed a shift in ASIA scale. A statistically significant association of these symptomatic improvements with the cell therapy intervention was established using McNemar’s Test. On electrophysiological studies, 2 showed improvement and 1 showed change in functional MRI [79] (Figure 6, Tables 1 and 2).



**Figure 6.** Symptomatic improvements in patients with spinal cord injury after stem cell therapy. The X-axis denotes symptoms presented in the patient population and the Y-axis denotes the number of patients. (ADLs—activities of daily living) (Tables 1 and 2).

Symptom/function	Affected patients (n of 110)	Patients improved (n)	Chi-square value <sup>†</sup>	P value <sup>‡</sup>
Spasticity	96	25	23.04	<0.0001
Sensation	108	30	28.033	<0.0001
Bladder management	48	16	14.06	0.0002
Bowel management	109	1	0	1.000*
Trunk control	23	22	20.045	<0.0001
Sitting balance	77	63	61.016	<0.0001
Standing balance	110	73	70.014	<0.0001
Wheelchair-bound to walking	77	17	15.059	0.0001
ADLs	99	59	57.017	<0.0001

Notes: \*Significant at  $P \leq 0.05$ ; <sup>†</sup>Chi-square value at one degree of freedom; <sup>‡</sup>P value insignificant for improvement in bowel management.

Abbreviation: ADLs, activities of daily living.

**Table 1.** Statistical significance for each symptomatic/functional change using McNemar’s test.



(A)	Nerve/sites	Amplitude 2-4 mV (before)	Amplitude 2-4 mV (after)	
Patient 1	R tibial (knee)-AH ankle	3.5	5.4	
	R tibial (knee)-AH knee	2.7	5.1	
	L tibial (knee)-AH ankle	4.1	5.7	
	R tibial (knee)-gastrocnemius knee	7.2	14.8	
	L tibial (knee)-gastrocnemius knee	10.2	11.7	
Patient 2	L common peroneal-EDB ankle	0.8	3.0	
	R common peroneal – tibialis anterior, fibular head	1.6	3.4	
	L common peroneal – tibialis anterior, fibular head	1.8	4.3	
	R tibial (knee)-AH ankle	7.0	8.0	
	L tibial (knee)-AH ankle	7.9	8.3	
	R tibial (knee)-gastrocnemius knee	6.2	18.7	
	L tibial (knee)-gastrocnemius knee	2.5	17.2	
	(B)	Functional MRI (before)	Functional MRI (after)	
	Patient 1	No activity in the pre and post central gyri	Activation in the right precentral gyrus	

Abbreviations: AH, abductor hallucis; EDB, extensor digitorum brevis; MRI, magnetic resonance imaging; R, right; L, left.

**Table 2.** Objective improvements evident on electromyography (A) and functional magnetic resonance imaging (B) after stem cell therapy in selected patients.

### 6.2.2 Cervical SCI

A detailed analysis of chronic cervical SCI patients who underwent intrathecal administration of autologous bone marrow mononuclear cells followed by neurorehabilitation was conducted [85]. This study includes 50 patients of chronic cervical SCI. The outcome was recorded at a mean follow up of 2 years  $\pm$  1 month. The outcome measures were functional independence measure (FIM) score, American Spinal Injury Association scale (ASIA) and detailed neurological assessment. Data were statistically analyzed using McNemar’s Test to establish significance between the change in symptoms and the intervention. 37 out of 50 (74%) showed improvements. Sensation recovery was observed in 26% cases, improved trunk control in 22.4%, spasticity reduction in 20% and bladder sensation recovery in 14.2%. All the 50 cases had improvement in postural hypotension. 12.24% wheelchair bound patients started walking with assistance. Functionally, 20.4% patients showed improved ADLs and 48% showed a positive change in FIM score. 6% cases showed a shift in ASIA scale. A statistical analysis using McNemar’s test established a significant association of these symptoms with the intervention [89]. No major side effects were noted in the duration of 2 years in both the studies. A better outcome was observed in thoracolumbar injury as compared to the cervical injury suggesting that the level of SCI greatly influences the recovery of the patient (Tables 3–5). Both studies demonstrated statistically significant clinical and functional outcome (Figure 7).

Symptom	No. of patients affected	No. of patients improved	McNemars test value	P value
Spasticity	49	9	7.11111	*0.00766
Sensation	51	11	9.09091	*0.00257
Bladder Sensation	34	7	5.14286	*0.02334
Upper Limb Strength	50	26	24.03846	*<0.000001
Sitting Balance	32	28	26.03571	*<0.000001
Standing Balance	56	27	25.03704	*<0.000001
Walking Balance	56	8	6.125	*0.01333
Trunk Stability	13	12	10.08333	*0.0015
Trunk muscle strength	9	7	5.14286	*0.02334
Postural Hypotension	11	11	9.09091	*0.00257

\*significant at p value  $\leq$  0.05

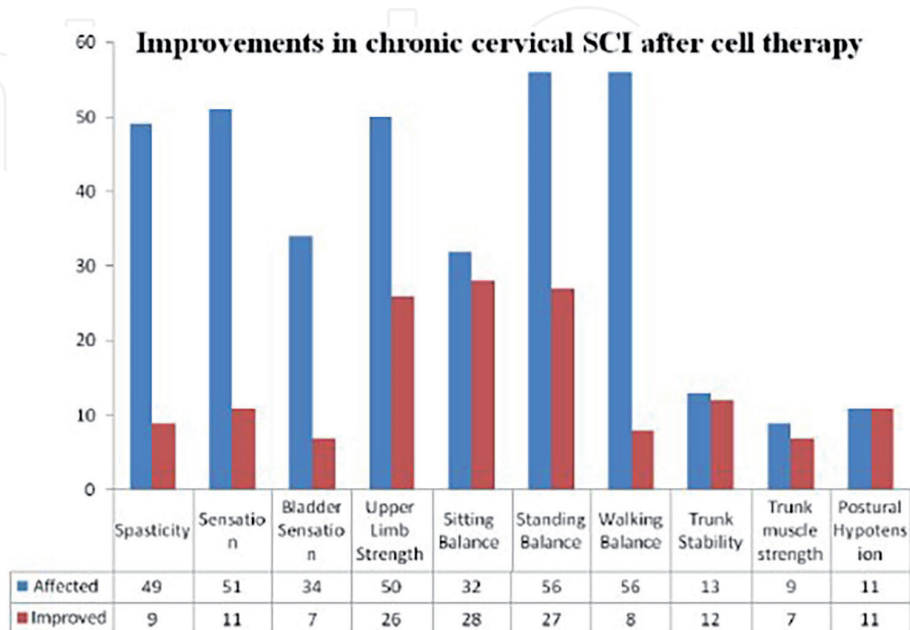
**Table 3.** McNemar’s test: table demonstrating the statistical analysis for each symptomatic improvement in cervical SCI using McNemar’s test.

Factors		Percentage improvements
Age	<18 yrs	100%
	18-35 yrs	41%
	>35 yrs	42%
Cause of Trauma	RTA	37.20%
	Non-RTA	30%
Chronicity	1-3 yrs	47.82%
	3-5 yrs	33.33%
	>5 yrs	44.44%
Rehabilitation	Done	36.84%
	Not Done	55.55%

**Table 4.**  
Percentage analysis of improvements: table demonstrating a detailed analysis of various factors and the improvements.

Symptoms improved	Cervical SCI	Thoracolumbar SCI
Spasticity	18.37%	26%
Sensation	21.57%	28%
Bladder Sensation	20.59%	33%
Bowel Sensation	5.66%	0.9%
Sitting Balance	87.50%	81.81%
Standing Balance	48.21%	66.36
Trunk Stability	92.31%	95.65%
Postural Hypotension	100.00%	100%

**Table 5.**  
Comparison between cervical SCI and thoracolumbar SCI: table comparing the outcome of cell transplantation in cervical SCI and thoracolumbar SCI.



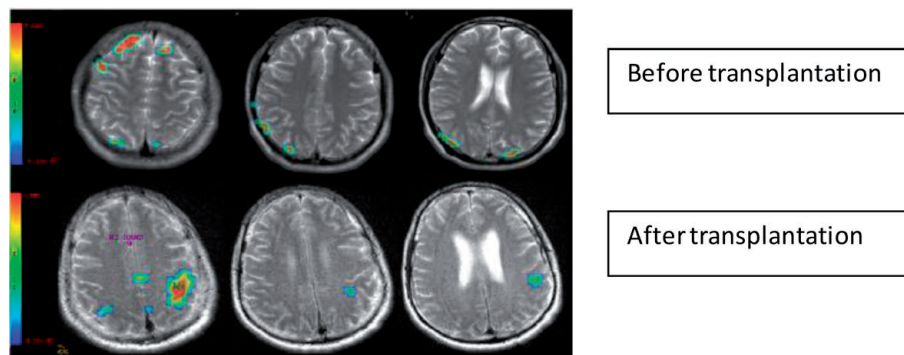
**Figure 7.**  
Graph demonstrating symptomatic improvements in chronic cervical SCI patients after cell therapy.



### 6.2.3 Objective assessment using neuroimaging

A case study of a 32-year-old man with chronic thoracic complete spinal cord injury treated with intrathecal administration of autologous bone marrow mononuclear cells with standard rigorous neurorehabilitation showed improved clinical outcome without any adverse effect [93]. Follow up assessment conducted at 3- and 7-months post treatment showed improvements in motor activities, ambulation, bed mobilities, transfers and bladder management. Spinal cord independence measure (SCIM) improved from 27 to 64/100 and functional improvement measure (FIM) improved from 64 to 83 suggesting significant functional gain.

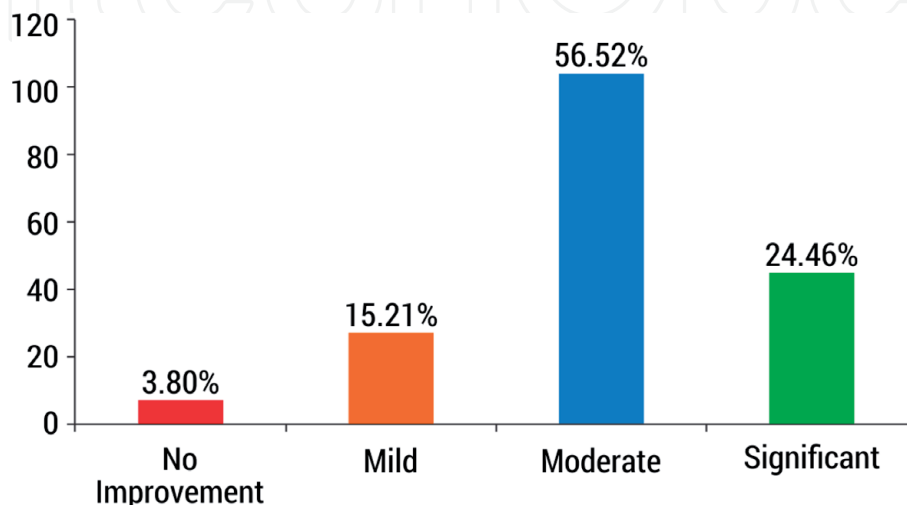
Brain functional magnetic resonance imaging (fMRI) shows patterns of cortical activation in response to attempted motor task. In chronic spinal cord injury cortico-spinal tract neurons undergo retrograde degeneration. Therefore, the activation of the cortical areas is reduced in response to injury. Brain fMRI can thus be used to assess the outcome of the therapy. Post treatment fMRI in these patients showed activation of multiple regions in the sensory and associated areas, which was absent pre-treatment providing evidence for improved neural activation (**Figure 8**).



**Figure 8.** fMRI images showing improved activation of sensorimotor and associated areas post transplantation.

### 6.3 Unpublished data

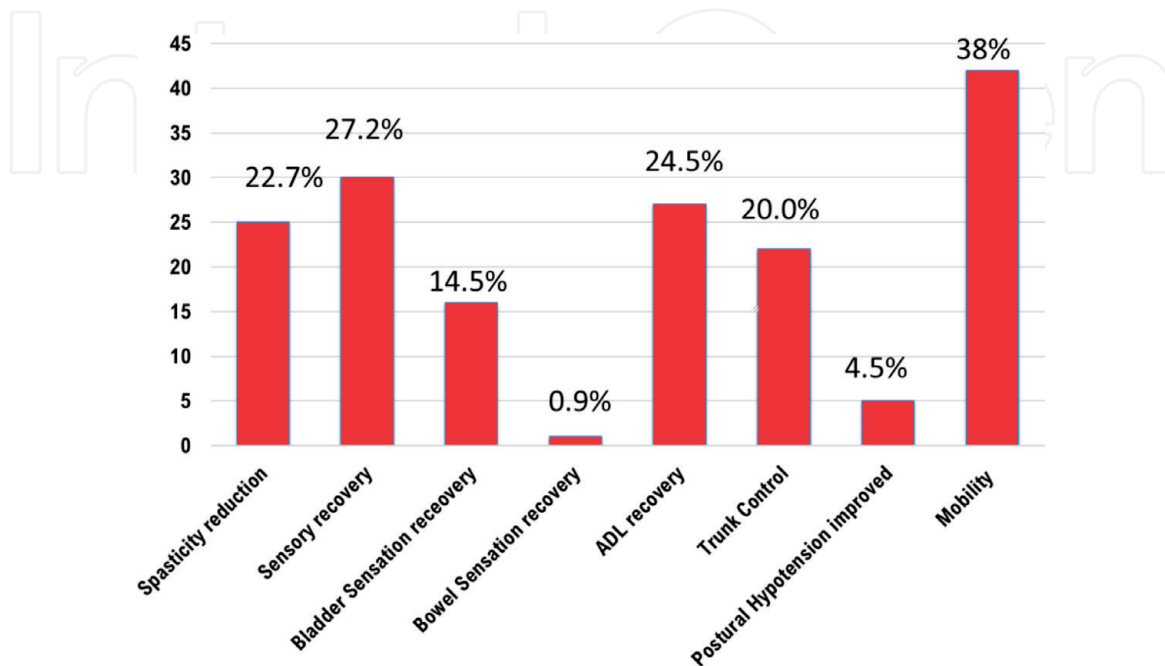
We analyzed 300 patients with chronic thoracic and cervical spinal cord injury and noted that 96.2% of the patients showed clinical improvements. The improvements were classified as mild, moderate or significant based on how many



**Figure 9.** Clinical outcome in patients with SCI post cell treatment.

symptoms showed improvements (3 symptoms—mild improvement, 4–6 symptoms—moderate improvement and more than 6 symptoms—significant improvement) majority of the patients showed moderate improvements (**Figure 9**).

Symptomatic analysis of these patients showed reduction in spasticity, sensory motor recovery, recovery of bladder sensation, increased functional independence while performing ADLS, improved balance and ambulation (**Figure 10**).



**Figure 10.**  
*Symptomatic improvements in patients with SCI post cell therapy.*

## 7. Limitations and future directions

Currently little objective evidence is available to show the regeneration of spinal cord and increased connectivity of spinal tracts. Enhanced radio imaging tools are required for better visualization of the outcome.

Although various cells and routes of administration have been explored an optimum cell type and route of administration remain elusive due to heterogeneity of research protocols, sample size, treatment regimen and lack of multi-centric high-quality studies. Comparison between different protocols is required to be carried out using rigorous methodology to identify an optimum clinical protocol that yields maximum recovery.

It takes about 6 months to generate iPSCs from autologous somatic cells and almost a year to test the safety of cells for transplantation, this combines with risks associated with iPSCs including genetic and epigenetic abnormalities, tumorigenicity and immunogenicity related to cell trans-plantation has prevented their clinical translation so far [94–96]. Advent in iPSC technology and its clinical translation is the future direction for medical sciences.

## 8. Conclusion

Spinal cord injury is a devastating and disabling neurological disorder with no definite cure. Several treatment strategies are being explored for improved clinical

outcome especially for chronic injuries. Stem cell therapy is a promising treatment modality. Use of stem cells for the treatment of spinal cord injury is safe and improves neurological as well as functional outcome. With the available evidence autologous multipotent stem cells like bone marrow derived mononuclear cells show positive clinical outcomes with no adverse effects. Factors like level of injury, time since injury, concomitant disorders and rigor of neurorehabilitation can influence the outcome of the cell treatment.

Lot of evidence has been generated over the last decade demonstrating the benefits of using stem cells to improve sensory-motor function, functional independence of the patients and quality of life. Stem cell therapy helps to reduce the complications post spinal cord injury due to their positive effect. Although it does not provide a complete cure at the moment, it certainly holds the potential to improve functional independence and quality of life. It is important to supplement stem cell therapy with current treatments and rehabilitation for optimum clinical improvement.


IntechOpen

### **Author details**

Alok Sharma, Hemangi Sane, Nandini Gokulchandran, Prerna Badhe,  
Amruta Paranjape\*, Pooja Kulkarni and Vivek Nair  
NeuroGen Brain and Spine Institute, Navi Mumbai, India

\*Address all correspondence to: [amrutap.neurogen@gmail.com](mailto:amrutap.neurogen@gmail.com)

### **IntechOpen**

© 2019 The Author(s). Licensee IntechOpen. This chapter is distributed under the terms of the Creative Commons Attribution License (<http://creativecommons.org/licenses/by/3.0>), which permits unrestricted use, distribution, and reproduction in any medium, provided the original work is properly cited. 

## References

- [1] Silva NA, Sousa N, Reis RL. From basics to clinical: A comprehensive review on spinal cord injury. *Progress in Neurobiology*. 2014;**114**:25-57
- [2] Wyndaele M, Wyndaele JJ. Incidence, prevalence and epidemiology of spinal cord injury: What learns a worldwide literature survey? *Spinal Cord*. 2006;**44**(9):523
- [3] Lee BB, Cripps RA, Fitzharris M, et al. The global map for traumatic spinal cord injury epidemiology: Update, global incidence rate. *Spinal Cord*. 2011;**52**(2):110-116
- [4] Zhao H, Sun QL, Duan LJ, Yang YD, Gao YS, Zhao DY, et al. Is cell transplantation a reliable therapeutic strategy for spinal cord injury in clinical practice? A systematic review and meta-analysis from 22 clinical controlled trials. *European Spine Journal*. 2019;**21**:1092-1112
- [5] Hurlbert RJ, Hadley MN, Walters BC, et al. Pharmacological therapy for acute spinal cord injury. *Neurosurgery*. 2015;**76**:S71-S83
- [6] Miller SM. Methylprednisolone in acute spinal cord injury: A tarnished standard. *Journal of Neurosurgical Anesthesiology*. 2008;**20**(2):140-142
- [7] Yue JK, Chan AK, Winkler EA, Upadhyayula PS, Readdy WJ, Dhall SS. A review and update on the guidelines for the acute management of cervical spinal cord injury—Part II. *Journal of Neurosurgical Sciences*. 2016;**60**(3):367-384
- [8] Ditunno JF, Cardenas DD, Formal C, Dalal K. Advances in the rehabilitation management of acute spinal cord injury. *Handbook of Clinical Neurology*. 2012;**109**:181-195
- [9] Marino G, Rosso F, Ferdinando P, et al. Growth and endothelial differentiation of adipose stem cells on polycaprolactone. *Journal of Biomedical Materials Research. Part A*. 2012;**100**(3):543-548
- [10] Barbarisi M, Marino G, Armenia E. Use of polycaprolactone (PCL) as scaffolds for the regeneration of nerve tissue. *Journal of Biomedical Materials Research. Part A*. 2015;**103**(5):1755-1760
- [11] Sahni V, Kessler JA. Stem cell therapies for spinal cord injury. *Nature Reviews. Neurology*. 2010;**6**(7):363-372
- [12] Ruff CA, Wilcox JT, Fehlings MG. Cell-based transplantation strategies to promote plasticity following spinal cord injury. *Experimental Neurology*. 2012;**235**(1):78-90
- [13] Frantz S. Embryonic stem cell pioneer Geron exits field, cuts losses. *Nature Biotechnology*. 2012;**30**:12-13
- [14] Geffner LF, Santacruz P, Izurieta M, Flor L, Maldonado B, Auad AH, et al. Administration of autologous bone marrow stem cells into spinal cord injury patients via multiple routes is safe and improves their quality of life: Comprehensive case studies. *Cell Transplantation*. 2008;**17**(12):1277-1293
- [15] El-Kheir WA, Gabr H, Awad MR, Ghannam O, Barakat Y, Farghali HA, et al. Autologous bone marrow-derived cell therapy combined with physical therapy induces functional improvement in chronic spinal cord injury patients. *Cell Transplantation*. 2014;**23**(6):729-745
- [16] Zhou Q, Zhang SZ, Xu RX, Xu K. Neural stem cell transplantation and postoperative management: Report of 70 cases. *Di Yi Jun Yi Da Xue Xue Bao*. 2004;**24**(10):1207-1209



- [17] Moviglia GA, Fernandez Viña R, Brizuela JA, et al. Combined protocol of cell therapy for chronic spinal cord injury. Report on the electrical and functional recovery of two patients. *Cytotherapy*. 2006;**8**(3):202-209
- [18] Knoller N, Auerbach G, Fulga V, et al. Clinical experience using incubated autologous macrophages as a treatment for complete spinal cord injury: Phase I study results. *Journal of Neurosurgery. Spine*. 2005;**3**(3):173-181
- [19] Cristante F, Barros-Filho TEP, Barros-Filho TEP. Stem cells in the treatment of chronic spinal cord injury: Evaluation of somatosensitive evoked potentials in 39 patients. *Spinal Cord*. 2009;**47**(10):733-738
- [20] Ichim TE, Solano F, Lara F, et al. Feasibility of combination allogeneic stem cell therapy for spinal cord injury: A case report. *International Archives of Medicine*. 2010;**3**:30
- [21] Lima P, Escada J, Pratas-Vital J, et al. Olfactory mucosal autografts and rehabilitation for chronic traumatic spinal cord injury. *Neurorehabilitation and Neural Repair*. 2010;**24**(1):10-22
- [22] Ra JC, Shin IS, Kim SH, Kang SK, Kang BC, Lee HY, et al. Safety of intravenous infusion of human adipose tissue-derived mesenchymal stem cells in animals and humans. *Stem Cells and Development*. 2011;**20**(8):1297-1308
- [23] Raisman G. Repair of spinal cord injury by transplantation of olfactory ensheathing cells. *Comptes Rendus Biologies*. 2007;**330**(6-7):557-560
- [24] Huang H, Xi H, Chen L, Zhang F, Liu Y. Long-term outcome of olfactory ensheathing cell therapy for patients with complete chronic spinal cord injury. *Cell Transplantation*. 2012;**21**(Suppl 1):S23-S31
- [25] Saberi H, Firouzi M, Habibi Z, Moshayedi P, Aghayan HR, Arjmand B, et al. Safety of intramedullary Schwann cell transplantation for post rehabilitation spinal cord injuries: 2-year follow-up of 33 cases. *Journal of Neurosurgery. Spine*. 2011;**15**(5):515-525
- [26] Yazdani SO, Hafizi M, Zali AR, Atashi A, Ashrafi F, Seddighi AS, et al. Safety and possible outcome assessment of autologous Schwann cell and bone marrow mesenchymal stromal cell co-transplantation for treatment of patients with chronic spinal cord injury. *Cytotherapy*. 2013;**15**(7):782-791
- [27] Sun T, Ye C, Zhang Z, Wu J, Huang H. Co transplantation of olfactory ensheathing cells and Schwann cells combined with treadmill training promotes functional recovery in rats with contused spinal cords. *Cell Transplantation*. 2013;**22**(Suppl 1):S27-S38
- [28] Chen L, Huang H, Xi H, Zhang F, Liu Y, Chen D, et al. A prospective randomized double-blind clinical trial using a combination of olfactory ensheathing cells and Schwann cells for the treatment of chronic complete spinal cord injuries. *Cell Transplantation*. 2014;**23**(Suppl 1):S35-S44
- [29] Al-Zoubi A, Jafar E, Jamous M, Al-Twal F, Al-Bakheet S, Zalloum M, et al. Transplantation of purified autologous leukapheresis-derived CD34+ and CD133+ stem cells for patients with chronic spinal cord injuries: Long-term evaluation of safety and efficacy. *Cell Transplantation*. 2014;**23**(Suppl 1):S25-S34
- [30] Cheng H, Liu X, Hua R, Dai G, Wang X, Gao J, et al. Clinical observation of umbilical cord mesenchymal stem cell transplantation in treatment for sequelae of thoracolumbar spinal cord injury. *Journal of Translational Medicine*. 2014;**12**:253



- [31] Syková E, Jendelová P, Urdzíkova L, Lesný P, Hejcl A. Bone marrow stem cells and polymer hydrogels-two strategies for spinal cord injury repair. *Cellular and Molecular Neurobiology*. 2006;**26**(7-8):1113-1129
- [32] Syková E, Homola A, Mazanec R, et al. Autologous bone marrow transplantation in patients with subacute and chronic spinal cord injury. *Cell Transplantation*. 2006;**15**:1-100
- [33] Chernykh R, Stupak VV, Muradov GM, et al. Application of autologous bone marrow stem cells in the therapy of spinal cord injury patients. *Bulletin of Experimental Biology and Medicine*. 2007;**143**(4):543-547
- [34] Frasch M. Dedifferentiation, redifferentiation, and trans differentiation of striated muscles during regeneration and development. *Current Topics in Developmental Biology*. 2016;**116**:331-355
- [35] Jopling C, Boue S, Belmonte JC. Dedifferentiation, trans-differentiation and reprogramming: Three routes to regeneration. *Nature Reviews. Molecular Cell Biology*. 2011;**12**(2):79
- [36] Baker CL, Pera MF. Capturing totipotent stem cells. *Cell Stem Cell*. 2018;**22**(1):25-34
- [37] Singh VK, Saini A, Kalsan M, Kumar N, Chandra R. Describing the stem cell potency: The various methods of functional assessment and in silico diagnostics. *Frontiers in Cell and Development Biology*. 2016;**4**:134
- [38] Alizadeh A, Dyck SM, Karimi-Abdolrezaee S. Traumatic spinal cord injury: An overview of pathophysiology, models and acute injury mechanisms. *Frontiers in Neurology*. 2019;**10**:282
- [39] Keirstead HS, Nistor G, Bernal G, Totoiu M, Cloutier F, Sharp K, et al. Human embryonic stem cell-derived oligodendrocyte progenitor cell transplants remyelinate and restore locomotion after spinal cord injury. *The Journal of Neuroscience*. 2005;**25**(19):4694-4705
- [40] Karimi-Abdolrezaee S, Eftekharpour E, Wang J, Morshead CM, Fehlings MG. Delayed transplantation of adult neural precursor cells promotes remyelination and functional neurological recovery after spinal cord injury. *The Journal of Neuroscience*. 2006;**26**(13):3377-3389
- [41] Dasari VR, Spomar DG, Gondi CS, Sloffer CA, Saving KL, Gujrati M, et al. Axonal remyelination by cord blood stem cells after spinal cord injury. *Journal of Neurotrauma*. 2007;**24**(2):391-410
- [42] Akiyama Y, Radtke C, Kocsis JD. Remyelination of the rat spinal cord by transplantation of identified bone marrow stromal cells. *The Journal of Neuroscience*. 2002;**22**(15):6623-6630
- [43] Pineau I, Lacroix S. Proinflammatory cytokine synthesis in the injured mouse spinal cord: Multiphasic expression pattern and identification of the cell types involved. *The Journal of Comparative Neurology*. 2007;**500**:267-285
- [44] Kettenmann H, Hanisch UK, Noda M, Verkhratsky A. Physiology of microglia. *Physiological Reviews*. 2001;**91**:461-553
- [45] Oyinbo CA. Secondary injury mechanisms in traumatic spinal cord injury: A nugget of this multiply cascade. *Acta Neurobiologiae Experimentalis (Wars)*. 2011;**71**:281-299
- [46] Kong X, Gao J. Macrophage polarization: A key event in the secondary phase of acute spinal cord injury. *Journal of Cellular and Molecular Medicine*. 2017;**21**:941-954. DOI: 10.1111/jcmm.13034

- [47] Saporta S, Kim JJ, Willing AE, Fu ES, Davis CD, Sanberg PR. Human umbilical cord blood stem cells infusion in spinal cord injury: Engraftment and beneficial influence on behavior. *Journal of Hematotherapy & Stem Cell Research*. 2003;12(3):271-278
- [48] Urdzíkova L, Růžicka J, LaBagnara M, Kárová K, Kubinová Š, Jiráková K, et al. Human mesenchymal stem cells modulate inflammatory cytokines after spinal cord injury in rat. *International Journal of Molecular Sciences*. 2014;15(7):11275-11293
- [49] Kim Y, Jo SH, Kim WH, Kweon OK. Antioxidant and anti-inflammatory effects of intravenously injected adipose derived mesenchymal stem cells in dogs with acute spinal cord injury. *Stem Cell Research & Therapy*. 2015;6(1):229
- [50] Cheng Z, Zhu W, Cao K, Wu F, Li J, Wang G, et al. Anti-inflammatory mechanism of neural stem cell transplantation in spinal cord injury. *International Journal of Molecular Sciences*. 2016;17(9):1380
- [51] Urdzíkova L, Jendelová P, Glogarová K, Burian M, Hájek M, Syková E. Transplantation of bone marrow stem cells as well as mobilization by granulocyte-colony stimulating factor promotes recovery after spinal cord injury in rats. *Journal of Neurotrauma*. 2006;23(9):1379-1391
- [52] Kumagai G, Okada Y, Yamane J, Nagoshi N, Kitamura K, Mukaino M, et al. Roles of ES cell-derived gliogenic neural stem/progenitor cells in functional recovery after spinal cord injury. *PLoS ONE*. 2009;4(11):e7706
- [53] Kim HM, Hwang DH, Lee JE, Kim SU, Kim BG. Ex vivo VEGF delivery by neural stem cells enhances proliferation of glial progenitors, angiogenesis, and tissue sparing after spinal cord injury. *PLoS ONE*. 2009;4(3):e4987
- [54] Quertainmont R, Cantinieaux D, Botman O, Sid S, Schoenen J, Franzen R. Mesenchymal stem cell graft improves recovery after spinal cord injury in adult rats through neurotrophic and pro-angiogenic actions. *PLoS ONE*. 2012;7(6):e39500
- [55] Ogawa Y, Sawamoto K, Miyata T, Miyao S, Watanabe M, Nakamura M, et al. Transplantation of in vitro-expanded fetal neural progenitor cells results in neurogenesis and functional recovery after spinal cord contusion injury in adult rats. *Journal of Neuroscience Research*. 2002;69(6):925-933
- [56] Deng YB, Liu XG, Liu ZG, Liu XL, Liu Y, Zhou GQ. Implantation of BM mesenchymal stem cells into injured spinal cord elicits de novo neurogenesis and functional recovery: Evidence from a study in rhesus monkeys. *Cytotherapy*. 2006;8(3):210-214
- [57] Lu P, Jones LL, Snyder EY, Tuszynski MH. Neural stem cells constitutively secrete neurotrophic factors and promote extensive host axonal growth after spinal cord injury. *Experimental Neurology*. 2003;181(2):115-129
- [58] Smith AG. Embryo-derived stem cells: Of mice and men. *Annual Review of Cell and Developmental Biology*. 2001;17:435-462. DOI: 10.1146/annurev.cellbio.17.1.435
- [59] Nistor GI, Totoiu MO, Haque N, Carpenter MK, Keirstead HS. Human embryonic stem cells differentiate into oligodendrocytes in high purity and myelinate after spinal cord transplantation. *Glia*. 2005;49:385-396
- [60] Cloutier F, Siegenthaler MM, Nistor G, Keirstead HS. Transplantation of human embryonic stem cell-derived oligodendrocyte progenitors into rat spinal cord injuries does not cause harm. *Regenerative Medicine*. 2006;1:469-479

- [61] Salewski RP, Mitchell RA, Shen C, Fehlings MG. Transplantation of neural stem cells clonally derived from embryonic stem cells promotes recovery after murine spinal cord injury. *Stem Cells and Development*. 2015;**24**:36-50
- [62] Faulkner J, Keirstead HS. Human embryonic stem cell-derived oligodendrocyte progenitors for the treatment of spinal cord injury. *Transplant Immunology*. 2005;**15**:131-142
- [63] Zhang YW, Denham J, Thies RS. Oligodendrocyte progenitor cells derived from human embryonic stem cells express neurotrophic factors. *Stem Cells*. 2006;**15**:943-952
- [64] Tetzlaff W, Okon EB, Karimi-Abdolrezaee S, Hill CE, Sparling JS, Plemel JR, et al. A systematic review of cellular transplantation therapies for spinal cord injury. *Journal of Neurotrauma*. 2011;**28**:1611-1682
- [65] Salewski RP, Mitchell RA, Li L, Shen C, Milekovskaia M, Nagy A, et al. Transplantation of induced pluripotent stem cell-derived neural stem cells mediate functional recovery following thoracic spinal cord injury through remyelination of axons. *Stem Cells Translational Medicine*. 2015;**4**:743-754
- [66] Shende P, Subedi M. Pathophysiology, mechanisms and applications of mesenchymal stem cells for the treatment of spinal cord injury. *Biomedicine & Pharmacotherapy*. 2017;**91**:693-706
- [67] Nagoshi N, Okano H. Applications of induced pluripotent stem cell technologies in spinal cord injury. *Journal of Neurochemistry*. 2017;**141**:848-860
- [68] Fujimoto Y, Abematsu M, Falk A, Tsujimura K, Sanosaka T, Juliandi B, et al. Treatment of a mouse model of spinal cord injury by transplantation of human induced pluripotent stem cell-derived long-term self-renewing neuroepithelial-like stem cells. *Stem Cells*. 2012;**30**:1163-1173
- [69] Kobayashi Y, Okada Y, Itakura G, Iwai H, Nishimura S, Yasuda A, et al. Pre-evaluated safe human iPSC-derived neural stem cells promote functional recovery after spinal cord injury in common marmoset without tumorigenicity. *PLoS ONE*. 2012;**7**:e52787
- [70] Nutt SE, Chang EA, Suhr ST, Schlosser LO, Mondello SE, Moritz CT, et al. Caudalized human iPSC-derived neural progenitor cells produce neurons and glia but fail to restore function in an early chronic spinal cord injury model. *Experimental Neurology*. 2013;**248**:491-503
- [71] Amemori T, Ruzicka J, Romanyuk N, Jhanwar-Uniyal M, Sykova E, Jendelova P. Comparison of intraspinal and intrathecal implantation of induced pluripotent stem cell-derived neural precursors for the treatment of spinal cord injury in rats. *Stem Cell Research & Therapy*. 2015;**6**:257
- [72] Hayashi K, Hashimoto M, Koda M, Naito AT, Murata A, Okawa A et al. Increase of sensitivity to mechanical stimulus after transplantation of murine induced pluripotent stem cell-derived astrocytes in a rat spinal cord injury model. *Journal of Neurosurgery Spine*. Dec 2011;**15**(6):582-593
- [73] Rabinovich SS, Seledtsov VI, Poveschenko OV. Transplantation treatment of spinal cord injury patients. *Biomedicine & Pharmacotherapy*. 2003;**57**(9):428-433
- [74] Feron F, Perry C, Cochrane J, Licina P, Nowitzke A, Urquhart S, et al. Autologous olfactory ensheathing cell transplantation in human spinal cord injury. *Brain*. 2005;**128**(12):2951-2960



- [75] Mackay-Sim F, Féron J, Cochrane J, et al. Autologous olfactory ensheathing cell transplantation in human paraplegia: A 3-year clinical trial. *Brain*. 2008;**131**(9):2376-2386
- [76] Subbaiah GPV, Adavi V, Chelluri LK, Laxman S, Ratnakar KS, Gopal PBN, et al. Preliminary report on the safety, efficacy and functional recovery of spinal cord injury with autologous bone marrow derived mesenchymal stem cells—A clinical trial. *The Internet Journal of Spine Surgery*. 2009;**5**(1)
- [77] Jarocha D, Milczarek O, Kawecki Z, Wendrychowicz A, Kwiatkowski S, Majka M. Preliminary study of autologous bone marrow nucleated cells transplantation in children with spinal cord injury. *Stem Cells Translational Medicine*. Mar 2014;**3**(3):395-404
- [78] Ha Y, Yoon SH, Park SR. Treatment of complete spinal cord injury patients receiving autologous bone marrow cell transplantation and bone marrow stimulation with granulocyte macrophage-colony stimulating factor—Report of three cases. *Journal of Korean Neurosurgical Association*. 2004;**35**:459-464
- [79] Park HC, Shim YS, Ha Y, et al. Treatment of complete spinal cord injury patients by autologous bone marrow cell transplantation and Administration of granulocyte-macrophage colony stimulating factor. *Tissue Engineering*. 2005;**11**(5-6):913-922
- [80] Deda H, Inci MC, Kürekçi AE, Kayihan K, Özgün E, Ustünsoy GE, et al. Treatment of chronic spinal cord injured patients with autologous bone marrow-derived hematopoietic stem cell transplantation: 1-year follow-up. *Cytotherapy*. 2008;**10**(6):565-574
- [81] Frolov AA, Bryukhovetskiy AS. Effects of hematopoietic autologous stem cell transplantation to the chronically injured human spinal cord evaluated by motor and somatosensory evoked potentials methods. *Cell Transplantation*. 2012;**21**(Suppl 1): S49-S55
- [82] Dai G, Liu X, Zhang Z, Yang Z, Dai Y, Xu R. Transplantation of autologous bone marrow mesenchymal stem cells in the treatment of complete and chronic cervical spinal cord injury. *Brain Research*. 2013;**1533**:73-79
- [83] Jiang PC, Xiong WP, Wang G, Ma C, Yao WQ, Kendell SF, et al. A clinical trial report of autologous bone marrow-derived mesenchymal stem cell transplantation in patients with spinal cord injury. *Experimental and Therapeutic Medicine*. 2013;**6**(1):140-146
- [84] Sharma A, Gokulchandran N, Sane H, Badhe P, Kulkarni P, Lohia M, et al. Detailed analysis of the clinical effects of cell therapy for thoracolumbar spinal cord injury: An original study. *Journal of Neurorestoratology*. 2013;**1**:13-22
- [85] Sharma A, Sane H, Gokulchandran N, Kulkarni P, Thomas N, et al. Role of autologous bone marrow mononuclear cells in chronic cervical spinal cord injury—A Long-term follow up study. *Journal of Neurological Disorders*. 2013;**1**:138
- [86] Abdelaziz OS. Feasibility, safety, and efficacy of directly transplanting autologous adult bone marrow stem cells in patients with chronic traumatic dorsal cord injury: A pilot clinical study. *Neurosurgery Quarterly*. 2010;**20**(3):216-226
- [87] Saberi H, Moshayedi P, Aghayan H-R, et al. Treatment of chronic thoracic spinal cord injury patients with autologous Schwann cell transplantation: An interim report on safety considerations and possible

outcomes. *Neuroscience Letters*. 2008;**443**(1):46-50

[88] Park JH, Kim DY, Sung IY, et al. Long-term results of spinal cord injury therapy using mesenchymal stem cells derived from bone marrow in humans. *Neurosurgery*. 2012;**70**(5):1238-1247

[89] Saito F, Nakatani T, Iwase M, et al. Spinal cord injury treatment with intrathecal autologous bone marrow stromal cell transplantation: The first clinical trial case report. *The Journal of Trauma*. 2008;**64**(1):53-59

[90] Pal R, Venkataramana NK, Bansal A, et al. Ex vivo expanded autologous bone marrow-derived mesenchymal stromal cells in human spinal cord injury/ paraplegia: A pilot clinical study. *Cytotherapy*. 2009;**11**(7):897-911

[91] Kumar A, Kumar SR, Narayanan R, Arul K, Baskaran M. Autologous bone marrow derived mononuclear cell therapy for spinal cord injury: A phase I/ II clinical safety and primary efficacy data. *Experimental and Clinical Transplantation*. 2009;**7**(4):241-248

[92] Callera F, do Nascimento RX. Delivery of autologous bone marrow precursor cells into the spinal cord via lumbar puncture technique in patients with spinal cord injury: A preliminary safety study. *Experimental Hematology*. 2006;**34**(2):130-131

[93] Alok S, Prerna B, Suhasini P, Hemangi S, Samson N, Pooja K, et al. Functional recovery and functional magnetic resonance imaging changes following cellular therapy in a case of chronic complete spinal cord injury. *Current Trends in Clinical & Medical Imaging*. 2017;**1**(4):555566

[94] Okano H, Nakamura M, Yoshida K, Okada Y, Tsuji O, Nori S, et al. Steps toward safe cell therapy using induced pluripotent stem cells. *Circulation Research*. 2013;**112**:523-533

[95] Nishimura S, Yasuda A, Iwai H, et al. Time-dependent changes in the microenvironment of injured spinal cord affects the therapeutic potential of neural stem cell transplantation for spinal cord injury. *Molecular Brain*. 2013;**6**:3

[96] Iwai H, Shimada H, Nishimura S, et al. Allogeneic neural stem/progenitor cells derived from embryonic stem cells promote functional recovery after transplantation into injured spinal cord of nonhuman primates. *Stem Cells Translational Medicine*. 2015;**4**:708-719